

Anti-inflammatory Effect of Tamarillo (*Solanum betaceum* Cav.) Fruit Peel Ethanol Extract: Study of Carrageenan-Induced Buccal Mucosa on Rats

Amiretta Syarafina, Janti Sudiono

Oral Pathology Department, Faculty of Dentistry, Universitas Trisakti
Jakarta, Indonesia

Received : 22-04-2022

Accepted : 06-05-2022

Published : 22-05-2023

Corresponding author: Prof. drg. Janti Sudiono, M.DSc., Sp.PMM(K)

Oral Pathology Department, Faculty of Dentistry, Universitas Trisakti

Jl. Kyai Tapa No. 1, Jakarta Barat 11440

Indonesia

e-mail: jantish@trisakti.ac.id

ABSTRACT

Background

Inflammation is a local protective response by tissue damage. Tamarillo fruit peel ethanol extract has flavonoid as anti-inflammatory, anti-oxidant, inhibit cyclooxygenase and lipoxygenase as well as leukocyte accumulation. This study aims to determine anti-inflammatory effect of Tamarillo fruit peel ethanol extract on carrageenan-induced buccal mucosa of rats.

Methods

Extraction was done by maceration with 70% ethanol. The 30 rats divided into five groups, namely positive control (diclofenac sodium), negative control (NaCl), and extract doses of 70, 140 and 280 mg/kgBW. Carrageenan was injected as inflammation inducer in the right buccal mucosa. Macroscopic and microscopic observations were performed at three times, 24, 48, and 72 hours after carrageenan injection.

Results

At 24 hours, inflammatory cells of 70 mg/kg extract were 37, at 140 and 280 mg/kgBW were 18; positive and negative control as 35 and 405. At 48 hours, inflammatory cells of positive control were 22; extract of 70, 140, and 280 mg/kgBW were 21, 17, and 16 while negative control was 26. At 72 hours, positive and negative controls were 18 and 27. Extract of 70, 140, and 280 mg/kgBW had 20, 12 and 9 cells. Extract groups had no significant differences with the positive control ($p>0.05$) except for the 48th hours of 70 mg/kgBW however the extract groups showed significance with negative control ($p<0.05$). The lowest number cells (6) was at 280 mg/kgBW on 72 hours.

Conclusion

Tamarillo fruit peel ethanol extract is effective anti-inflammatory agent especially dose of 280 mg/kgBW on 72 hours.

Keywords: inflammatory cells, Tamarillo fruit peel ethanol extract, carrageenan, buccal mucous.

INTRODUCTION

Inflammation is a local protective response due to tissue damage by physical trauma, destructive chemical or microbiological agents.¹ Inflammation is a body effort to non-activate the invasion organism, eliminate irritant and prepare the process of tissue repair.² Inflammatory process is marked by cardinal signs include calor, tumor, rubor, dolor and function laesa. Along the inflammatory process, chemical mediator released such as histamine, 5-hydroxytryptamine, chemotactic factor, bradykinin, leukotriene, and prostaglandin.³

Usually, inflammation can be treated by steroid and non-steroid anti-inflammatory drugs. Common population used to the anti-inflammatory chemical drugs due to its ability to remove inflammation rapidly however there is also give harmful side effect risk include disturbances of gastrointestinal, blood, respiratory, metabolic, hypersensitivity, and Reye syndrome.⁴ Therefore anti-inflammatory herbal medicine become more needed.⁵

Indonesian population has used to herbal remedies as traditional medicine caused of their very minimal side effect suspected, more safety, and easier to be found compared to those of other medicine.⁶ Indonesia has a lot of herbal trees, at least there are 30.000 herbal trees with 7.500 among them have herbal medicine properties.⁷⁻⁹ Parts of herbal trees can be used as herbal medicine such as fruit, flower, skin, leaves, and rhizome.¹⁰

One of the herbal trees that started to be used a lot as herbal remedies is Dutch eggplant or Tamarillo (*Solanum betaceum* Cav.).¹¹ Tamarillo is fruit of *Solanaceae* family originated from sub tropic area. Nowadays, the fruit of tamarillo is more cultivated by farmers in Tanah Karo, North of Sumatera.¹² Parts of tamarillo that commonly used is its fruit as anti-oxidant resources. Its skin is not much used therefore it becomes garbage while actually it contains anthocyanin, beta caroten, phenol, and flavonoid.¹³ Previous study revealed that compound with anti-inflammatory potential is flavonoid. Flavonoid able to prevent cyclooxygenase or lipooxygenase and leucocyte accumulation within inflammation area and has anti-inflammatory effect potency.¹⁴ Flavonoid compound within ethanol extract of tamarillo skin fruit with its antioxidant property has included in quercetin group.¹⁵ This anti oxidant compound hind the response of inflammation by eliminate the

free radical tissue destruction which insisted the biosynthesis of arachidonate acid and hinder cyclooxygenase enzyme and prostaglandin formation.¹⁶

There are several chemical irritants that can be used to study the anti-inflammatory effect, one of them is carrageenan.^{17,18} Carrageenan induction has been used as a method to decide in vivo anti-inflammatory activity. This method can be used as carrageenan is an irritant compound inducer for the damage of cells resulted in releasing mediator inducer of inflammation process. Therefore, carrageenan also can be used to study anti-inflammatory medical properties by giving this acute inflammatory chemical in vivo without resulting destruction of tissue in injection area.¹⁹

Up to know, there is a little study about the anti-inflammatory effectivity of Tamarillo fruit peel ethanol extract. Therefore, it is needed to do more research about it to understand its anti-inflammatory effect. The purpose of this study is to find out the anti-inflammatory effect of tamarillo (*Solanum betaceum* Cav.) fruit peel ethanol extract on buccal mucous of rat induced by carrageenan injection.

METHODS

a. Type of study.

Experimental laboratory in vivo.

b. Place.

This study was done at Animal Research Facilities (ARF) IMERI Faculty of Medicine Universitas Indonesia, Pathology Anatomy Laboratory CMU 2 dr. Cipto Mangunkusumo Hospital and at Faculty of Dentistry, Universitas Trisakti, on December 2021. The ethical clearance from Ethical Committee Medical Research Faculty of Medicine, Universitas Indonesia, dr. Cipto Mangunkusumo, number: KET-762/UN2.F1/ETIK/PPM.00.02/ 2021.

c. Animal research.

The research samples used were male white rat (*Rattus norvegicus*) strain Wistar with age of 3 to 4 months and body weight of 150-240g from Animal Vet Laboratorium Service. The number of samples according to Federer formula $\{(t-1)(n-1) \geq 15\}$ with the sample groups (15) and (n=2) were 30. Sample groups which divided into 3 times of examination (24, 48, 72 hours) are diclofenac sodium (7mg/kgBW) as positive control, sodium chloride as negative

control, and tamarillo (*Solanum betaceum* Cav.) fruit peel ethanol extract with dose of 70, 140, and 280 mg/kgBW as treatment groups. After 30 minutes given orally with specific solution for each specific group, samples injected submucous by inflammatory induced solution (carrageenan) on right buccal mucous. The examination was done on 24, 48, and 72 hours after injection.

d. Fruit peel tamarillo extract.

Extraction method used in this study was maceration technique with ethanol 70% solution. The extract divided into 3 doses which are 70, 140, and 280 mg/kgBW.²⁰

e. Anti inflammation evaluation.

Inflammation was examined macroscopic and microscopically. Macroscopic examination was done through the measurement of body weight and the thickness of buccal mucous using digital caliper with the main axis at the injection site. The measurement was done at before, 24, 48, and 72 hours after carrageenan injection.

f. Tissue sample preparation.

The Wistar rat was given euthanasia procedure on 24, 48, and 72 hours after carrageenan injection by given lethal dose of ketamine and xylazine injection. The tissue samples of buccal mucous were excised for the microscopic evaluation.

g. Microscopic examination.

Inflammatory respond examined through histopathological slide of each sample using digital microscope and magnification of 400 on 3 examination areas. The inflammatory parameter evaluation based on the polymorphonuclear (PMN) leucocytes and lymphocyte infiltration on buccal mucous tissue by counting the number of inflammatory cells of each area using ImageJ application. The steps of counting inflammatory cells by ImageJ version 1.53 was shown on Figure 1.

h. Counting and scoring inflammatory cells by Image J.

After counting the inflammatory cells at 3 area examination from 30 histopathological slides the average of each group was then counting and categorized based on the inflammation score result. Inflammation score was done by 4 criterias (Table 1) as followed: 0 (none), 1 (light), 2 (moderate), and 3 (severe).

i. Data analysis

Data was analyzed by software SPSS. Macroscopic data was analysed by normality test using *Shapiro-Wilk*. If the data normally distribution continued by comparative test using *One Way ANOVA* with p value decided as 0.05, if there is significant differences ($p < 0.05$), followed by *Post Hoc* LSD. Microscopic data was analyzed by non parametric test using *Kruskal-Wallis*, followed by *Post Hoc* Mann-Whitney.

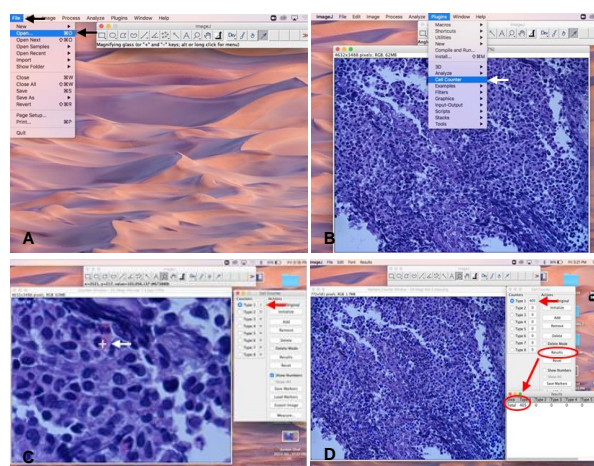


Figure 1. Step of using *ImageJ* application to count inflammatory cells. A. First, open the *ImageJ* application then click "File" at the left top of the application display, after that click "Open" and select an image from the buccal mucous slide and then "Open". B. Second, to count the inflammatory cells, click "Plugin" and "Cell counter". C. Third, an active window "Cell Counter" will appear, after that click on the inflammatory cells showed on slide and then the "Cell Counter" was shown on active window. If the inflammatory cells are less visible, "Zoom in" slide feature. D. Click "Results" to see the total count of inflammatory cells of slide and save the feature of slide with counting and table counting result of inflammatory cells.

Table 1. Microscopic score of inflammatory responds.²¹

Score	Respond of inflammatory
0	None, inflammatory cells 0
1	Light, inflammatory cells <25
2	Mild, inflammatory cells 25-124
3	Severe, inflammatory cells >125

RESULT

Phytochemical test

Phytochemical test in this study using qualitative method with the result showed that tamarillo (*Solanum betaceum* Cav.) fruit peel ethanol extract contain phenolic compound, flavonoid, tannin and alkaloid (Table 2).

Table 2. Phytochemical test of tamarillo (*Solanum betaceum* Cav.) fruit peel ethanol extract.

Secondary metabolit	Test method	Result
Phenolic	FeCl ₃ 5%	+
Flavonoid	a. Concentrated HCl + Mg	+
	b. H ₂ SO ₄ 2N	+
	c. NaOH 10%	+
Steroid	Lieberman-Burchard reagent	-
Triterpenoid	Lieberman-Burchard reagent	-
Saponin	HCl + H ₂ O	-
Tannin	FeCl ₃ 1%	+
Alkaloid	a. Hager reagent	+
	b. Wagner reagent	+
	c. Dragendorff reagent	+

Macroscopic evaluation

The buccal mucous thickness at before, 24, 48, 72 hours after carrageenan injection was shown on Table 3 while macroscopic features of inflammation on buccal mucous was shown on Figure 2.

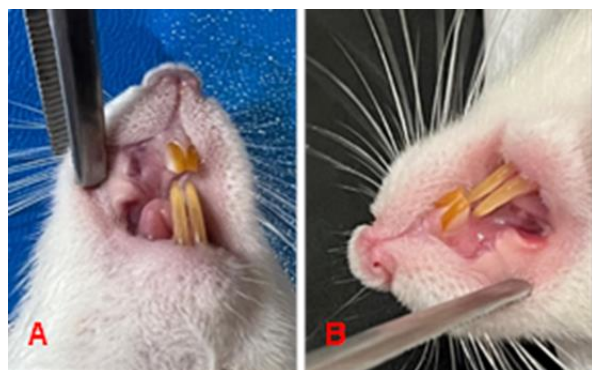

Figure 2. Macroscopic features of inflamed buccal mucous. A. Before carrageenan injection: buccal mucous looks pale. B. After carrageenan injection: buccal mucous looks slightly red.

Table 3. The thickness of buccal mucous (% recovery).

Treatment groups	Time		
	24 hours	48 hours	72 hours
Positive control	62%	26%	89%
Negative control	32%	11%	53%
Extract 70 mg/kgBW	42%	28%	61%
Extract 140 mg/kgBW	56%	51%	63%
Extract 280 mg/kgBW	61%	51%	80%

Normality test with *Shapiro Wilk* as shown on Table 3, data was normal distributed ($p > 0.05$). *One Way ANOVA* test showed significant differences ($p < 0.05$) among groups. *LSD* test showed that no significant differences between positive control and extract 70 mg/kgBW at 48 hours ($p > 0.05$).

The body weight measurement before, 24, 48, 72 hours after carrageenan injection was shown on Table 4.

Table 4. The body weight measurement (% weight loss).

Treatment groups	Time		
	24 hours	48 hours	72 hours
Positive control	0,78%	-1,51%	-2,76%
Negative control	-1,22%	-3,07%	-3,64%
Extract 70 mg/kgBW	0,27%	-3,9%	-1,89%
Extract 140 mg/kgBW	-1,95%	-1,08%	-3,08%
Extract 280 mg/kgBW	0,31%	-4,92%	-4,31%

Normality test with *Shapiro Wilk* was shown on Table 4, data was normal distributed ($p > 0.05$). *One Way ANOVA* test was shown on Table 3 with the significant differences among the fifth treatment groups at the all three examination times ($p < 0.05$).

Microscopic evaluation

Microscopic examination based on the number rate of inflammatory cells with its inflammation score of each group was shown on Table 5.

Table 5. The average of inflammatory cells number and inflammation score of buccal mucous.

Treatment groups	Time					
	24 hours		48 hours		72 hours	
	Average of number cells	Inflammation score	Average of number cells	Inflammation score	Average of number cells	Inflammation score
Positive control	30	2	20	1	15	1
Positive control	18	1	16	1	11	1
Negative control	157	3	22	1	23	1
Negative control	215	3	25	2	26	2
Extract 70 mg/kgBW	27	2	19	1	20	1
Extract 70 mg/kgBW	24	1	23	1	19	1
Extract 140 mg/kgBW	19	1	17	1	18	1
Extract 140 mg/kgBW	24	1	18	1	13	1
Extract 280 mg/kgBW	17	1	16	1	12	1
Extract 80 mg/kgBW	17	1	17	1	6	1

Kruskal-Wallis test at Table 5 showed significant differences ($p < 0.05$) at all three examinations time, however Mann-Whitney test showed that there was no significant differences between positive control and those of three doses of extract ($p > 0.05$). There was also no significant difference between extract group of 24 and 48 hours after carrageenan injection ($p > 0.05$). On 48 hours, there was shown no significant difference between negative control and extract 70 mg/kgBW group ($p > 0.05$). On 72 hours, there was also no significant differences among groups ($p > 0.05$).

Microscopic evaluation showed on Figure 3, 4, and 5.

On 24 hours, the inflammatory cells as PMN accumulation were dominated by neutrophil and eosinophil (Figure 3). The severe inflammatory cell was found on negative control group while among the three doses of extract, the severe inflammatory cell was found on the doses of 70 mg/kgBW.

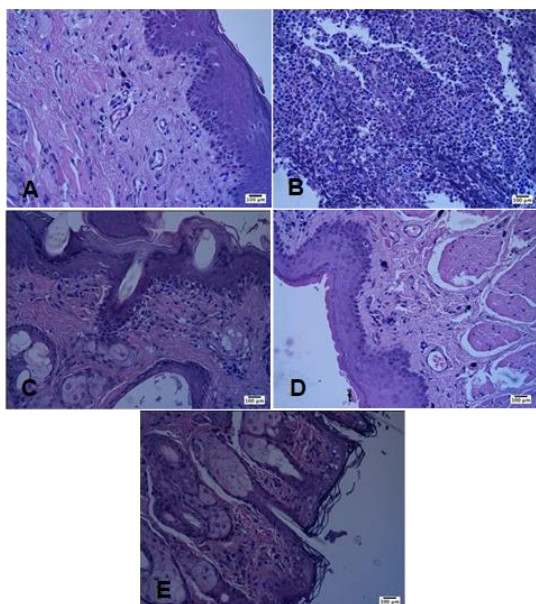


Figure 3. The number of inflammatory cells on 24 hours post treatment groups (HE: Magnification 400 times). A. Positive control: 35 cells. B. Negative control: 405 cells. C. 70 mg/kgBW extract: 37 cells. D. 140 mg/kgBW extract: 18 cells. E. 280 mg/kgBW extract: 18 cells.

On 48 hours, there was still accumulation of PMN at all treatment groups however lymphocyte cells started occurred (Figure 4). On 72 hours, there was decrease of inflammatory cells at all treatment groups whereas lymphocyte

cells at negative control and 70 mg/kgBW group showed higher than those of other groups (Figure 5).

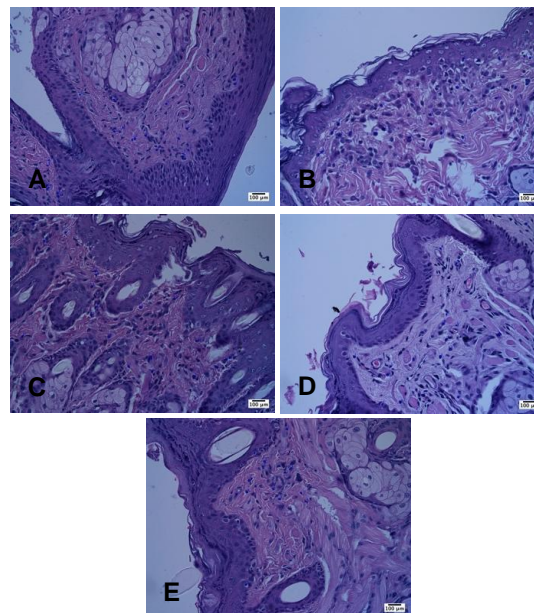


Figure 4. The number of inflammatory cells on 48 hours post treatment groups (HE: Magnification 400 times). A. Positive control: 22 cells. B. Negative control: 26 cells. C. 70 mg/kgBW extract: 21 cells. D. 140 mg/kgBW extract: 17 cells. E. 280 mg/kgBW extract: 16 cells.

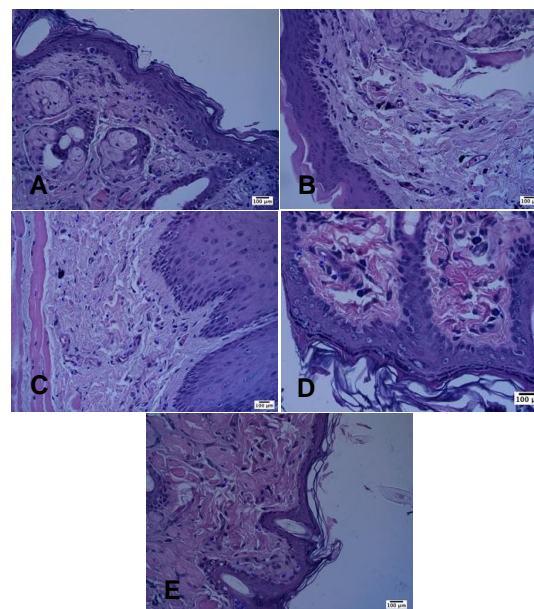


Figure 5. The number of inflammatory cells on 72 hours post treatment groups (HE: Magnification 400 times). A. Positive control: 18 cells. B. Negative control: 27 cells. C. 70 mg/kgBW extract: 18 cells. D. 140 mg/kgBW extract: 16 cells. E. 280 mg/kgBW extract: 6 cells.

DISCUSSION

Inflammation is a local protective response caused by tissue damage due to physical trauma, destructive chemical or microbiological substances that involve various physiological processes in the body.^{1,22} Inflammation treatments that are easily found and have a fast effect are chemical anti-inflammatory drugs. Traditional medicine using herbal plant has also been carried out by Indonesian population, one of them is Tamarillo.

This study used Tamarillo fruit peel that was extracted by maceration method and made into three doses, namely 70, 140 and 280 mg/kgBW. Male Wistar rats were given diclofenac sodium as a positive control, NaCl as a negative control, and three doses of the extract orally before carrageenan induction. It is intended that the extract can inhibit the release of inflammatory mediators so that inflammation is inhibited. Anti-inflammatory testing was carried out by counting the total of inflammatory cells microscopically and supported by macroscopic observations at 24, 48 and 72 hours after carrageenan injection. The increased thickness of the buccal mucous was caused by carrageenan which stimulated the release of prostaglandins after being injected into experimental animals.²³

Based on the results of statistical analysis, at the 24 hours, there was significant differences between the inflammation scores of Tamarillo fruit peel extract group at doses of 70, 140 and 280 mg/kgBW with the negative control group ($p < 0.05$) but there was no significant difference with the positive control group ($p > 0.05$). It means that the extract groups at doses of 70, 140, and 280 mg/kgBW were shown have anti-inflammatory activity in deed almost the same intensity as the positive control. These results were also supported by the macroscopic observations of the buccal mucous thickness and the body weight among groups that also showed significant differences ($p < 0.05$) at before and 24 hours after carrageenan injection.

At the 48 hours, the inflammation score of the negative control group had significant differences with the 140 and 280 mg/kgBW ($p < 0.05$) with the exception of the 70 mg/kg Tamarillo fruit peel extract. However, the positive control group and the three doses extract group did not have significant differences ($p > 0.05$). It means that at the 48 hours, the doses of 140 and 280 mg/kgBW had a slightly higher anti-

inflammatory effect compared to those of 70 mg/kgBW with the similar effects of these three doses of extracts to those of positive control group. From the supported data which is of macroscopic valuation that is 48 hours after injection of carrageenan, there was no significant difference in the thickness of the buccal mucous on the positive control and the 70 mg/kgBW group ($p > 0.05$). However, on the 48 hours, there was significant differences among the subject body weight of groups before and after carrageenan injection ($p < 0.05$).

At the 72 hours, there was no significant differences of the inflammation score among groups ($p > 0.05$). It means that at 72 hours, the five groups had a similar effect in reducing inflammation whereas at 72 hours they had entered a phase of inflammation reducing as well as on the negative control group. This might have happened due to the natural mechanism of the body in reducing inflammation. However, it was different with the thickness of the buccal mucosa and body weight before and after carrageenan injection at the 72 hours groups whereas there was still showed significant differences among groups ($p < 0.05$).

Figure 3, 4, and 5 showed that the extract group showed a decrease in inflammatory cells therefore their numbers became the lowest over time. At the 24 hours, all five groups were dominated by PMN cells and then at the 48 hours there was still an accumulation of PMN cells but the lymphocyte cells had appeared whereas the healing process had been seen while at the 72 hours they were dominated by lymphocyte cells. All of these due to the inflammatory phase started from the first 24th to 72th hours marked by the accumulation of PMN cells which increased from 24 to 48 hours and decreased after 72th hours.²⁴

In the Tamarillo fruit peel ethanol extract group, the lowest average number of inflammatory cells was 6 cells which were on the dose of 280 mg/kgBW at the 72 hours as shown on Table 5. This is in accordance with the results of macroscopic observations on Table 3 which showed that the Tamarillo fruit peel ethanol extract group had a higher percentage of buccal mucous thickness recovery compared to those of the negative control group especially at 72 hours but still lower than those of the positive control group. Nevertheless, the effect of carrageenan injection did not affect the body weight of the rats as shown on Table 4 that the body weight of the rats

increased with the exception on the positive control and the 70, 280 mg/kgBW group at the 24 hours.

Based on the results of the whole statistical analysis, the Tamarillo fruit peel ethanol extract had an anti-inflammatory effect on the buccal mucous of rats induced by carrageenan. This study is in line with the results of other studies which state that the Tamarillo fruit peel ethanol extract has anti-inflammatory effect due to the presence of compound components involved in anti-inflammatory activity namely flavonoid compounds.²⁰ The results of the phytochemical tests conducted in this study also showed that the Tamarillo fruit peel ethanol extract positively contained phenolic compounds, flavonoids, tannins, and alkaloids. Flavonoid compounds have been shown to have potential as anti-inflammatories by inhibiting cyclooxygenase or lipooxygenase and the accumulation of leukocytes in areas of inflammation.

CONCLUSION

The Tamarillo fruit peel ethanol extract is proven contain active compounds in form of flavonoids which have potential as an anti-inflammatory. Tamarillo fruit peel ethanol extract is effective in reducing inflammation especially at 72 hours with a dose of 280 mg/kgBW.

REFERENCES

- Agustina R, Indrawati DT, Masruhin MA. Aktivitas ekstrak daun salam (*Eugenia poyantha*) sebagai antiinflamasi pada tikus putih (*Rattus norvegicus*). *J Trop Pharm Chem*. 2015; 3(2):120-3.
- Harvey RA, Champe PC. *Farmakologi Ulasan Bergambar Edisi 4*. Jakarta: Penerbit Buku Kedokteran EGC; 2013.
- Susiloningrum D. Pengaruh Ekstrak Etanol Rimpang Temulawak (*Curcuma xanthorrhiza* Roxb.) terhadap Efek Ulserogenik Natrium Diklofenak pada Tikus [Skripsi]. Surakarta: Fakultas Farmasi Universitas Muhammadiyah Surakarta; 2012.
- Setyopuspito Pramitaningastuti A. Uji efektivitas antiinflamasi ekstrak etanol daun srikaya (*Annona Squamosa* L.) terhadap edema kaki tikus putih jantan galur wistar. *J Ilm Farm*. 2017; 13(1):8-14.
- Lee S-E, Lim C, Kim H, Cho S. A Study of the Anti-inflammatory Effects of the Ethyl Acetate Fraction of the Methanol Extract of *Forsythia* Fructus. *Afr J Tradit Complement Altern Med*. 2016; 13(5):102-13.
- Rivai H, Heriadi A, Fadhilah H. Pembuatan dan Karakterisasi Ekstrak Kering Daun Salam (*Syzigium polyanthum* (WIGHT) WALP). *J Farm Higea*. 2015; 7(1):54-62.
- Sibarani VR, Wowor PM, Awaloei H. Uji Efek Analgesik Ekstrak Daun Beluntas (*Pluchea indica* L.) pada Mencit (*Mus musculus*). *J e-Biomedik*. 2013; 1(1):621-8.
- Sudiono J, Fasikhin H. The Effect of Terung Belanda (*Cyphomandra betacea* Sendtn.) Peels Fruit Extract on Tongue Cancer Cells. *Biomed J Sci Tech Res*. 2020; 28(4).
- Qazi Majaz A, Molvi Khurshid I. Herbal medicine: A comprehensive review. *Int J Pharm Res*. 2016; 8(2):1-5.
- Umi Y, Siti H, Winda O, Ratu C. Aktivitas Antiinflamasi Ekstrak Etanol Buah dan Asam Jawa (*Tamarindus indica*) serta Kombinasinya pada Tikus Jantan Galur Wistar. *Pros SNaPP2015 Kesehat*. 2015; 83-8.
- Berawi KN, Asvita SM. Efektivitas ekstrak terong belanda untuk menurunkan kadar glukosa dan kolesterol LDL darah pada pasien obesitas. *Majority*. 2016; 5(1):102-6.
- Julianti E. Pengaruh tingkat kematangan dan suhu penyimpanan terhadap mutu buah terong belanda (*Cyphomandra betacea*). *J Hortik Indones*. 2012; 2(1):14.
- Mandal P, Ghosal M. Antioxidant activities of different parts of tree tomato fruit. *Int J Pharm Sci Rev Res*. 2012; 13(2):39-47.
- Narande JM, Wulur A, Yudistira A. Uji efek antiinflamasi ekstrak etanol daun suji (*Dracaena angustifolia* roxb) terhadap edema kaki tikus putih jantan galur wistar. *Pharmacon*. 2013; 2(3):14-8.
- Putri YI. Ekstraksi Kuersetin dari Kulit Terong Belanda (*Solanum betaceum* Cav.) Menggunakan Pelarut Etanol [Skripsi]. Medan: Fakultas Teknik Universitas Sumatera Utara; 2017.
- Aprilianto E. Uji Efek Antiinflamasi Infusa Kulit Alpukat (*Persea americana* Mill.) pada Mencit Jantan Galur Swiss Terinduksi Karagenin [Skripsi]. Yogyakarta: Fakultas Farmasi Universitas Sanata Dharma; 2017.
- Putri AK. Uji Aktivitas Antiinflamasi Ekstrak Daun Nangka (*Artocarpus heterophyllus* Lam.) pada Tikus Putih (*Rattus norvegicus*) dengan Induksi Karagen [Skripsi]. Surabaya:

- Fakultas Kedokteran Universitas Airlangga; 2016.
18. Kurniawan B, Carolia N, Thamrin AA. Uji efektivitas antiinflamasi ekstrak daun binahong (*Anredera cordifolia* (Ten.) Steenis) pada tikus jantan galur sprague dawley yang diinduksi karagenin. *Med Fac Lampung Univ.* 2013; 10-7.
 19. Setianto R, Dewi BA, Rosita F. Uji aktivitas antiinflamasi ekstrak etanol daun pangotan (*Microsorium beurgerianum* (Miq.) Ching) terhadap tikus putih (*Rattus norvegicus* L.) yang diinduksi karagenan. *J Ilm Kesehat.* 2020; 1(2).
 20. Priamsari MR, Krismonikawati RA. Uji daya antiinflamasi ekstrak etanolik kulit terong belanda (*Solanum betaceum* Cav.) pada mencit jantan yang diinduksi karagenin. *J Ilmu Farm dan Farm Klin.* 2020; 16(02):86.
 21. Karanth P, Manjunath MK, Roshni R, Kuriakose ES. Reaction of rat subcutaneous tissue to mineral trioxide aggregate and Portland cement: A secondary level biocompatibility test. *J Indian Soc Pedod Prev Dent.* 2013; 31(2):74-81.
 22. V. Stankov S. Definition of inflammation causes of inflammation and possible anti-inflammatory strategies. *Open Inflamm J.* 2012; 5(1):1-9.
 23. Necas J, Bartosikova L. Carrageenan: A review. *Vet Med (Praha).* 2013; 58(4):187-205.
 24. Agustin R, Dewi N, Rahardja SD. Efektivitas ekstrak ikan haruan (*Channa striata*) dan ibuprofen terhadap jumlah sel neutrofil pada proses penyembuhan luka studi in vivo pada mukosa bukal tikus (*Rattus norvegicus*) wistar. *J.Kedokt Gigi.* 2016; 1(1):68-74.