

The Von Hippel-Lindau Gene Product (Pvhl) Expression Profile in Pancreatic Ductal Adenocarcinoma and Non-Neoplastic Pancreatic Tissue and Its Correlation with Clinicopathological Factors

Jessica Prisscila¹, Marini Stephanie², Nur Rahadiani², Amelia F Manatar², Ening Krisnuhoni²

¹Anatomical Pathology Residency Program, ²Department of Anatomical Pathology, Faculty of Medicine Universitas Indonesia/Dr. Cipto Mangunkusumo Hospital, Jakarta, 10430, Indonesia

*Corresponding Author: Marini Stephanie, Department of Anatomical Pathology, Faculty of Medicine Universitas Indonesia/Dr. Cipto Mangunkusumo, Jakarta, Indonesia. Salemba Raya Street No. 6, Kenari, Senen, Central Jakarta, 10430, Indonesia. Email: marini2sh@gmail.com.

Received : 07-11-2023

Accepted : 10-11-2023

Published : 31-01-2026

ABSTRACT

Introduction

Pancreatic malignancy, primarily Pancreatic Ductal Adenocarcinoma (PDAC), presents a significant challenge due to its aggressive nature and late-stage diagnosis. This study explores the role of von Hippel-Lindau gene product (pVHL) in PDAC and non-neoplastic pancreatic tissues, investigating their relationship with PDAC clinicopathological characteristics.

Methods

This research was carried out at the Faculty of Medicine Universitas Indonesia/Dr. Cipto Mangunkusumo General Hospital. The cases analyzed spanned from January 2012 to September 2023. Immunohistochemistry of pVHL was used, and the HistoScore/H-score calculations were utilized to classify pVHL expression as either high or low.

Results

A total of 54 cases of PDAC and non-neoplastic pancreatic tissue exhibited varying levels of pVHL expression. Cases of PDAC with positive surgical margin, absence of lymphovascular and perineural invasion, pT2, pN0, M0 stage, and survival exceeding 7 months were the profiles in which low pVHL expression was detected. Significant result was found on the correlation between pVHL with pN status.

Conclusion

The levels of pVHL expression varied between PDAC and non-neoplastic pancreatic tissue. There were no differences in the clinicopathological profile of PDAC tumors, except for pN stage. Further research, with a larger sample size, is needed to determine pVHL's diagnostic value and its expression in different clinicopathological profiles.

Keywords: Pancreatic ductal adenocarcinoma, PDAC, pVHL, von Hippel-Lindau Gene Product.



INTRODUCTION

Pancreatic cancer exhibits a substantial fatality rate. In the year 2020, a total of 495 773 cases and 466,003 deaths were reported globally, with the highest incidence in Asia.^{1,2} The incidence of pancreatic cancer in Indonesia was recorded at 5 781 cases, and the mortality rate in the country was reported at 5 690 cases, ranking it as the 11th leading cause of death.¹

Pancreatic Ductal Adenocarcinoma (PDAC) is a prevalent malignancy, affecting 85-90% of pancreatic cancer cases. Only 20-25% are eligible for surgery, necessitating a biopsy or fine needle aspiration or with ultrasound guidance as the best option for PDAC diagnosis.³ However, distinguishing PDAC from non-neoplastic pancreatic disorders, particularly in cases of mass-forming chronic pancreatitis, remains challenging both radiologically and pathologically.^{4,5} Pathological examinations often reveal overlap between well-differentiated adenocarcinoma and reactive ductal epithelium, further emphasizing the need for specific markers to differentiate PDAC from non-neoplastic/reactive pancreatic tissue.^{6,7}

von Hippel-Lindau gene product (pVHL) is a protein produced by the VHL tumor suppressor gene located in the chromosome area 3p25-p26.⁸⁻¹⁰ pVHL plays a role in the degradation of hypoxia-inducible factor 1 α /HIF-1 α .^{9,11} The absence of normal pVHL function will cause HIF-1 α to evade the proteasomal degradation process and triggering the transcription, which is involved in angiogenesis, glucose metabolism, cell survival, and tumor progression.⁹ pVHL also has roles in both chromosome and p53 protein stabilization. Based on previous studies, pVHL expression in non-neoplastic pancreas can be found in the ducts, acini, and cells of the islets of Langerhans, while in PDAC cases, there is a loss of pVHL expression.^{5,12} There is limited research on the use of pVHL immunohistochemistry in studying PDAC and non-neoplastic cases, especially in relation to clinicopathological factors in Asian populations, specifically in Indonesia.^{11,13} Therefore, this study aims to determine pVHL expression in both PDAC and non-neoplastic pancreas tissues and assess pVHL expression based on various clinicopathological parameters of PDAC tumors, including tumor differentiation,

lymphovascular invasion, perineural invasion, surgical margin status, staging, and survival.

METHODS

This research is an observational analytical study employing a cross-sectional research design conducted at the Department of Anatomical Pathology, Faculty of Medicine Universitas Indonesia/Dr. Cipto Mangunkusumo General Hospital from August 2023 to October 2023.

The study began by collecting all paraffin blocks of all cases based on inclusion criteria, namely all cases of resected PDAC (designated as PDAC group) and non-PDAC pancreatic cases with sufficient areas of non-neoplastic pancreatic tissue (designated as non-neoplastic group) from January 2012 to September 2023. Cases with mixed histopathological diagnosis and those of which paraffin blocks were not available were excluded. Sample selection was carried out using simple random sampling from eligible cases that fulfilled the inclusion and exclusion criteria. Immunohistochemistry was performed on 3 to 4 μ m sections with antigen retrieval procedure using heat-induced epitope retrieval and non-specific protein blocker using Tissue Primary (containing 3% hydrogen peroxide), and Background Blocker, each for 20 minutes. Each section was incubated with mouse monoclonal primary antibody VHL40 sc-135657 (Santa Cruz Biotechnology) with a dilution of 1:100 for 60 minutes. Detection system using PolyVue™ Plus Mouse/Rabbit Enhancer, PolyVue™ Plus Mouse/Rabbit HRP label each for 15 minutes, and a mixture of 1 drop (50 μ l per drop) Stable DAB/Plus™ chromogen and 1 ml Stable DAB/Plus™ buffer for 30 seconds. Counter-staining was carried out using Mayer's Hematoxylin. Negative controls and positive controls were included in each batch, with the positive control being biliary epithelium of human gallbladder tissue, internal positive control being non-neoplastic pancreatic acini, and negative controls were preparations that were not incubated with primary antibodies. The expression of pVHL was evaluated by a pathology resident and a pathologist specialized in digestive and hepatobiliary pathology. Immunohistochemical staining was assessed through a light microscope (Olympus CX23), with observations made on tumor cells in the PDAC group and non-neoplastic



pancreatic ductal and asinar cells in the non-neoplastic group.

Immunohistochemical staining of pVHL was assessed in the cytoplasm and/or cell membrane, with or without staining in the cell nucleus. Cell staining (positivity) indicated retention of expression, while lack of staining (negativity) indicated loss of expression. Semiquantitative assessment was conducted using HistoScore/H-score calculations on 500 cells, based on the number of stained cells and the intensity of staining. The staining intensity was categorized as negative, weakly positive, moderately positive, and strongly positive. QuPath version 0.4.4 was used for all calculations. H-score calculation was done using the formula = (1x% weakly stained cells)+(2x% moderately stained cells)+(3x% strongly stained cells). To determine the cut-off value, the Receiver Operating Characteristic

(ROC) curve and the Youden index were used, with pVHL expression classified as 'high' if the H-score was greater than or equal to the cut-off and 'low' if it was lower than the cut-off. Data were analyzed using SPSS version 25.0.

RESULTS

Clinicopathological Profile of Research Subjects

The results of a search of archived data from the Department of Anatomical Pathology, FMUI/RSCM, from January 2012 to September 2023 revealed 28 cases of pancreatic resection in the PDAC group and 51 cases of pancreatic resection included in the non-neoplastic group. After excluding the 6 cases, a total of 27 PDAC cases and 27 cases of non-neoplastic cases were obtained. Demographic and clinicopathological data for all samples from this study can be seen in Table 1.

Table 1. Demographic and clinicopathological profile of cases (n=54).

Profile	PDAC (n=27) n (%)	Non-Neoplastic (n=27) n (%)
Age		
>50 years old	17 (63)	9 (33.3)
≤50 years old	10 (37)	18 (66.7)
Gender		
Male	16 (59.3)	5 (18.5)
Female	11 (40.7)	22 (81.5)
Degree of tumor differentiation		
Well differentiated	3 (11.1)	n/a
Moderately differentiated	20 (74.1)	n/a
Poorly differentiated	4 (14.8)	n/a
Lymphovascular invasion		
Present	9 (33.3)	n/a
Absent	18 (66.7)	n/a
Perineural invasion		
Present	9 (33.3)	n/a
Absent	18 (66.7)	n/a
Surgical margin status		
Positive	14 (51.9)	n/a
Negative	13 (48.1)	n/a
pT stage		
pT1	7 (25.9)	n/a
pT2	12 (44.4)	n/a
pT3	8 (29.6)	n/a
pT4	0 (0)	n/a
pN stage		
pN0	14 (51.9)	n/a
pN1	8 (29.6)	n/a
pN2	5 (18.5)	n/a
M stage		
M0	26 (96.3)	n/a
M1	1 (3.7)	n/a
Survival		
≤7 months	4 (14.8)	n/a
>7 months	4 (14.8)	n/a
Not yet determined	2 (7.4)	n/a
No data	17 (63.0)	n/a



The study found that most patients in the PDAC group were over 50 years old (mean age 54.4 ± 8.2 years old), with a median tumor size of 3 cm (range of 1 to 12 cm). Most subjects in the non-neoplastic group were ≤ 50 years old (mean age 37.85 ± 19.46 years old). Most tumors were moderately differentiated, with no lymphovascular or perineural invasion with positive surgical margin, pT2, pN0, and M0 stage. The mean survival of the patients is 5.5 months ± 3.62 months.

The average H-score obtained in all cases was 99.52 ± 67.15 , with the average H-score in the PDAC group being 99.95 ± 72.97 , and the median H-score in the non-neoplastic group was 88 (ranging from 2.6 to 241.7).

The Area Under Curve (AUC) on the ROC curve was made to determine the H-score cut-off value. The AUC of pVHL in this study was 47.7% (95% CI 31,9%-63,5%) with a p-value of 0.769. The cut-off value for H-score was 165.1 (sensitivity 25.9% and specificity 85.2%).

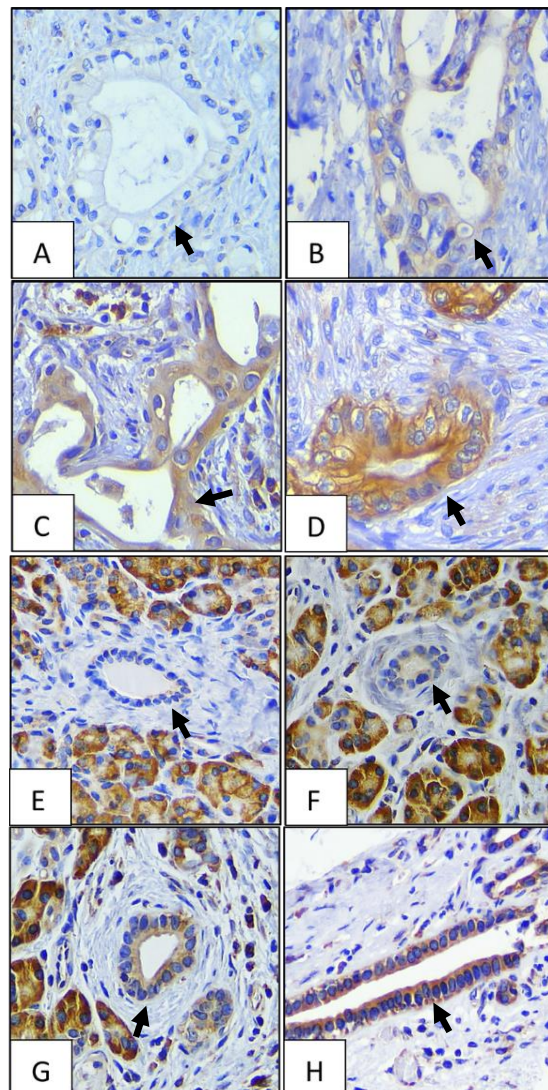


Figure 1. pVHL staining intensity in PDAC and Non-Neoplastic tissue (400 times magnification). A-D. PDAC (arrow): A. Negative, B. Weak positive, C. Moderate positive, D. Strong positive; E-H. Non-neoplastic (arrow): E. Negative, F. Weak positive, G. Moderate positive, H. Strong positive

Table 2. pVHL expression in PDAC and non-neoplastic pancreatic tissue based on predominant features (n=54).

pVHL expression	PDAC n (%)	Non-neoplastic	
		Ductus n (%)	Acinus n (%)
Negative	2 (7.4)	1 (3.7)	0 (0)
Weak positivity	14 (51.9)	15 (55.6)	0 (0)
Moderate positivity	10 (37)	8 (29.6)	0 (0)
Strong positivity	1 (3.7)	3 (11.1)	27 (100)



pVHL Expression based on PDAC Clinicopathological Profile

An analysis of the relationship between the clinicopathological profile and the pVHL expression category was conducted. As shown in Table 3, besides the significant difference in

pN stage, no significant differences found in other clinicopathological profile. Low pVHL expression is more common in PDAC with no lymphovascular or perineural invasion, positive surgical margin, pT2, pN0, M0 stage, and survival more than 7 months.

Table 3. Bivariate analysis of clinicopathological profile and pVHL expression in PDAC (n=27).

Clinicopathological Profile	pVHL expression		p-value	OR (95% CI)
	Low n (%)	High n (%)		
Degree of tumor differentiation				
Well differentiated*	3 (13)	0 (0)	1.000 ^f	Reference
Moderately differentiated*	16 (69.6)	4 (100)		n/a
Poorly differentiated	4 (17.4)	0 (0)		n/a
Lymphovascular invasion				
Present	6 (26.1)	3 (75)	0.093 ^f	0.118 (0,010-1.359)
Absent	17 (73.9)	1 (25)		
Perineural invasion				
Present	9 (39.1)	0 (0)	0.268 ^f	n/a
Absent	14 (60.9)	4 (100)		Reference
Surgical margin status				
Positive margin	13 (56.5)	1 (25)	0.326 ^f	3.900 (0.351-43.364)
Negative margin	10 (43.5)	3 (75)		
pT stage				
pT1	7 (30.4)	0 (0)	0.545 ^f	Reference
pT2*	10 (43.5)	2 (50)		n/a
pT3*	6 (26.1)	2 (50)		n/a
pT4 [^]	0 (0)	0 (0)		
pN stage				
pN0	14 (60.9)	0 (0)	0.041 ^f	Reference
pN1*	6 (26.1)	2 (50)		n/a
pN2*	3 (13)	2 (50)		n/a
M stage				
M0	22 (95.7)	4 (100)	1.000 ^f	Reference
M1	1 (4.3)	0 (0)		n/a
Survival				
≤ 7 months	3 (13)	1 (25)	1.000 ^f	n/a
> 7 months	4 (17.4)	0 (0)		Reference
Not yet determined [^]	2 (8.7)	0 (0)		
No data [^]	14 (60.9)	3 (75)		

*: analyzed after merged

[^]: not included in the analysis

f: Fischer's test

DISCUSSION

Clinicopathological Profile of Research Subjects

A large proportion of PDAC cases found in this study (37%) were found at ages ≤50 years old. According to the WHO 2019 report, most patients are diagnosed between the ages of 55 and 85, with a median age at diagnosis of 70 years old, which is older than the average age of PDAC patients in this study.¹⁴ Cases diagnosed with PDAC at a younger age (<50 years old) can be classified

as early onset pancreatic cancer (EOPC), a group predominantly composed of individuals of Asian descent, as indicated by previous studies. In our study, PDAC was more common among males.¹⁵ These findings might be related to the history of smoking, obesity, and alcohol consumption, which have long been recognized as risk factors for PDAC.^{14,16} Meanwhile, in non-neoplastic cases, a younger mean age was observed compared to the PDAC group.



In this study, lymphovascular and perineural invasion was found in 33.3% of the PDAC cases. These findings could be attributed to the tumor replacing endothelial cells and growing along the vascular wall, making it difficult to identify clear lymphovascular invasion, and the lack of adequate sampling in the peripancreatic area, which contains more vasculature and nerve fibers.^{17,18}

pVHL Expression based on PDAC Clinicopathological Profile

This study revealed no significant differences in pVHL expression related to the degree of differentiation, lymphovascular invasion, perineural invasion, surgical margin, pT and M stage, or survival in the PDAC group. The only significant differences were related to pN stage. The reduction in functional pVHL, an inhibitor of HIF, can lead to disinhibition of HIF and increased transcription of factors influencing angiogenesis and tumorigenesis. Therefore, pVHL expression should theoretically be reduced in tumors with higher grades and stages, which contradicts the findings of this research.^{8,9} While no other studies have linked pVHL expression to the clinicopathological profile in PDAC tumors, research on pVHL expression in renal clear cell carcinoma has shown that high pVHL expression protects against higher grades.¹⁹ The inconsistencies in pathological findings in this study may be attributed to the non-specific markers used.

This study's limited sample size limits its diagnostic utility, as it only serves as a comparative expression study. Additionally, no previous studies compare pVHL antibody staining in PDAC clinicopathological profiles, requiring larger samples for establishing diagnostic value. Further research is needed to specifically study the expression of pVHL in each clinicopathological profile of PDAC.

CONCLUSION

The levels of pVHL expression varied between PDAC and non-neoplastic pancreatic tissue. There were no differences in the clinicopathological profile of PDAC tumors, except for pN stage. Further research is needed to specifically study the expression of pVHL in each clinicopathological profile of PDAC.

AUTHORS' CONTRIBUTIONS

Study conception and design: Marini Stephanie, Nur Rahadiani. Data collection: Marini Stephanie, Nur Rahadiani, Ening Krisnuhoni, Amelia Fossetta, Jessica Prisscila. Analysis and interpretation of results: Jessica Prisscila, Marini Stephanie, and Nur Rahadiani. Manuscript drafting: Jessica Prisscila, Marini Stephanie, Nur Rahadiani. All authors reviewed the results and approved the final version of the manuscript.

ETHICAL APPROVAL

The present study (protocol no 23-09-1451) has been approved by the Medical Ethics Committee of the Faculty of Medicine, Universitas Indonesia/Dr. Cipto Mangunkusumo Hospital (approval no. KET-1314/UN2.F1/ETIK/PPM.00.02/2023).

CONFLICT OF INTERESTS

The authors declare that they have no conflict of interests.

REFERENCE

1. World Health Organization International Agency for Research on Cancer. GLOBOCAN 2020: Indonesia. Int Agency Res Cancer [Internet]. 2021 March [cited 2022 Apr]:1–2 Available from: <https://gco.iarc.fr/today/data/factsheets/populations/360-indonesia-fact-sheets.pdf>
2. World Health Organization International Agency for Research on Cancer. GLOBOCAN 2020: Pancreatic cancer fact sheet. Int Agency Res Cancer [Internet]. 2020 [cited 2022 Apr]:3–4. Available from: <https://gco.iarc.fr/today/fact-sheets-cancers>
3. Aksoy-Altinboga A, Baglan T, Umudum H, Ceyhan K. Diagnostic value of S100P, IMP3, maspin, and pVHL in the differential diagnosis of pancreatic ductal adenocarcinoma and normal/chronic pancreatitis in fine needle aspiration biopsy. *J Cytol.* 2018;35(4):247–51.
4. Schima W, Böhm G, Rösch CS, Klaus A, Függer R, Kopf H. Mass-forming pancreatitis versus pancreatic ductal adenocarcinoma: CT and MR imaging for differentiation. *Cancer Imaging.* 2020;20(1):1–12.
5. Lin F, Shi J, Liu H, Zhang J, Zhang PL, Wang HL, et al. Immunohistochemical



- detection of the von Hippel-Lindau gene product (pVHL) in human tissues and tumors a useful marker for metastatic renal cell carcinoma and clear cell carcinoma of the ovary and uterus. *Am J Clin Pathol.* 2008;129(4):592–605.
6. Luu TT. Review of immunohistochemistry biomarkers in pancreatic cancer diagnosis. *Front Oncol.* 2021;11(December):1–9.
 7. Lin F, Shi J, Liu H, Hull ME, Dupree W, Prichard JW, et al. Diagnostic utility of S100P and von Hippel-Lindau gene product (pVHL) in pancreatic adenocarcinoma - With implication of their role in early tumorigenesis. *Am J Surg Pathol.* 2008;32(1):78–91.
 8. Geismann C, Arlt A. Coming in the air: hypoxia meets epigenetics in pancreatic cancer. *Cells.* 2020;9(11):0–5.
 9. Minervini G, Pennuto M, Tosatto SCE. The pVHL neglected functions, a tale of hypoxia-dependent and -independent regulations in cancer. *Open Biol.* 2020;10(7).
 10. Sakashita N, Takeya M, Kishida T, Stackhouse TM, Zbar B, Takahashi K. Expression of von Hippel-Lindau protein in normal and pathological human tissues. *Histochem J.* 1999;31(2):133–44.
 11. Wu P, Zhang N, Wang X, Ning X, Li T, Bu D, et al. Family history of von Hippel-Lindau disease was uncommon in Chinese patients: Suggesting the higher frequency of de novo mutations in the VHL gene in these patients. *J Hum Genet.* 2012;57(4):238–43.
 12. Shen HCJ, Adem A, Ylaya K, Wilson A, He M, Lorang D, et al. Deciphering von hippel-lindau (VHL/Vhl)-associated pancreatic manifestations by inactivating Vhl in specific pancreatic cell populations. *PLOS One.* 2009;4(4).
 13. Wong M, Chu YH, Tan HL, Bessho H, Ngeow J, Tang T, et al. Clinical and molecular characteristics of East Asian patients with von Hippel-Lindau syndrome. *Chin J Cancer.* 2016;35(1):79.
 14. World Health Organization Classification of Tumors Editorial Board, editors. WHO classifications of tumours: digestive system tumours. 5th ed. WHO; 2019. p. 322-8.
 15. Ntala C, Debernardi S, Feakins RM, Crnogorac-Jurcevic T. Demographic, clinical, and pathological features of early onset pancreatic cancer patients. *BMC Gastroenterol.* 2018;18(1):1–12.
 16. Teng Y, Saito E, Abe SK, Sawada N, Iwasaki M, Yamaji T, et al. Female reproductive factors, exogenous hormone use, and pancreatic cancer risk: The Japan Public Health Center-based prospective study. *Eur J Cancer Prev.* 2017;26(5):378–84.
 17. Kim J. Cell Dissemination in Pancreatic Cancer. *Cells.* 2022;11(22):1–16.
 18. Campbell F, Verbeke CS. Pathology of the pancreas: a practical approach. London: Springer; 2013. p. 111-36.
 19. Ferchichi I, Kourda N, Sassi S, Romdhane K Ben, Balatgi S, Cremet JY, et al. Aurora A overexpression and pVHL reduced expression are correlated with a bad kidney cancer prognosis. *Dis Markers.* 2012;33(6):333–40.

